



Scopus® doi

Journal of Vibration Engineering



ISSN:1004-4523

Registered



SCOPUS



GOOGLE SCHOLAR



DIGITAL OBJECT
IDENTIFIER (DOI)



IMPACT FACTOR 6.1



Our Website
www.jove.science

Clinicopathologic and epithelial regression study in cutaneous warts of bovines infected by papillomavirus

Rachel Siqueira de Queiroz Simões Marins^{1*}; Prof. Carlos Eurico Pires Ferreira²

¹ Molecular Virology Laboratory, Virology Department, Oswaldo Cruz Foundation, Rio de Janeiro, Brazil,

² Ph.D. Microbiology, Animal Health Laboratory, Vet Hospital, State of North Fluminense Darcy Ribeiro University, Rio de Janeiro, Brazil.

Multiple tumor samples were collected from 32 bovines (*Bos taurus taurus* x *Bos taurus indicus*), of both sexes, bearers of pedunculated cutaneous flat and/or mixed papillomatosis. The samples were fixed in 10% buffered neutral formalin solution and submitted to histotechnique by inclusion in paraffin for hystopatologic analysis and used in the preparation of an autogenous inactivated vaccine for treatment. The objective of the present work is to show the clinical pathological finding and the classic cytomorphologic alterations associated with the infection of bovine papillomavirus and to accompany the epithelial lesion regression after three doses of vaccine. This vaccine program applied was effective not presenting any new injury in the 16 animals vaccinated after the experimental period.

KEY WORDS: *papillomavirus* infection, bovine cutaneous papillomatosis, cytomorphologic alterations, clinicopathologic findings and vaccine.

INTRODUCTION

Papillomaviruses (PVs) are highly species and site specific pathogens of stratified squamous and/or non stratified epithelium (Sundberg et al., 2000). They are classified as mucosotropic or cutaneotropic tropism (Souto et al., 2005). PVs induce the development of localized proliferative lesions of the skin and mucous in a wide range of hosts (Le Net et al., 1997). PVs are classified according to the International Committee on Taxonomy Virus - ICTV in the *Papillomavirus* genus of the *Papillomaviridae* family. They are double-stranded circular, non enveloped DNA viruses, of icosahedric symmetry, with 72 capsomeres. Their genome can be divided into three regions: a long control region (LCR) and gene products called open reading frames – (ORFs), where six genes are expressed precociously and two genes are expressed at a later time, being denominated respectively E (Early) and L (Late) (Campo, 1997; Sundberg et al., 2000). Their oncogenic potential is related to the viral proteins E6 and

E7, which are capable of interacting with proteins that regulate the cellular cycle and act as tumor suppressors. This interaction induces an uncontrollable regulation of the cellular cycle, causing the neoplasics formation (Souto et al., 2005). The initial infection by PV occurs in the basal layers. These basal cells differ and move forward in the direction of the epithelial surface layers. The production of PV is restricted to the suprabasal cells, where the daughter cells in the basal layer are not broken by the production of new infectious viral particles and continue proliferating as reservoir of viral DNA for future cellular divisions (Souto et al., 2005). Histopathologically, the bovine cutaneous papillomatosis is described as viral cytopathic effect known as Koilocytosis, considered being the “larger criterion” in the *papillomavirus* infection (Xavier et al., 2005). The objective of the present study is to evaluate the clinicopathologic findings and cytomorphologic classic alterations associated with *papillomavirus* infection through anatomopathologic exam of bovine clinical samples and to verify histologically the involution of the papilliform lesions after treatment with inactivated autogenous vaccine.



Figure 1. Bovine bearer of cutaneous papillomatosis with exophytic tumors located preferentially in the anatomic region of the head, neck, around the eyes and snout before autogenous vaccine treatment.



Figure 2. Macroscopic view of male bovine tumors with different morphologies before the initial treatment, presenting cauliflower aspect with dark color and another intermediate neoformations.

MATERIAL AND METHODS

Tumor samples were collected from 32 bovines (*Bos taurus taurus* x *Bos Taurus indicus*), of both sexes, clinically positive for cutaneous papillomatosis. These animals were divided into two groups with equal numbers of animals each: group 1 (control) with 16 animals that received no applications of vaccine and group 2 with 16 animals that were vaccinated. The neoplastic lesions were totally or partially removed by surgical incision or *punch*. The samples in copies were conserved appropriately and transported to the Laboratory for tissue processing by histopathology and preparation of inactivated autogenous vaccine.

Part of the tumors samples were fixed in 10% buffered neutral formalin solution, for at least 24 h, and sent to the Department of Morphology and Pathological Anatomy of the Animal Health Laboratory for histotechnique application. They were routinely embedded in paraffin, cut at 4 μm , and stained with haematoxylin and eosin (H&E). Another part of the samples was preserved in tubes under cooling for preparation of the inactivated autogenous vaccine at the Virology and Viruses Department of the Animal Health Laboratory at the State University of North Fluminense Darcy Ribeiro. We evaluated the antigenicity and immunogenicity of the vaccine by the immune response of Balb/C mouse challenged. After manipulation, three doses of 3mL each of the autogenous

vaccine were applied subcutaneously to the animals under test with seven day intervals between the applications. Before each vaccinal dose administration, samples were collected for the histopathologic analysis and epithelial regression study. The animals were observed in a 60 days period after the last application.

RESULTS

The tumors were exophytic and located especially in the dewlap, but the warts were also present on the neck, on the head, around the eyes, udder, teat and back (figure1). Clinical evaluation revealed mixed lesions with tumors some circumscribed, occasionally ulcerated and others with irregular morphology, with gray and dark color, some with presence of hair, adhered to the skin and flat, another pedunculated form with cauliflower aspect and intermediate neoformations that assumed characteristics in the sessile and pedunculated lesions (figure 2). In some lesions melanin granules ranging in



Figure 3. Contention of the same male bovine for vaccine treatment, surgical extraction of verrucous lesions for histopathology analysis to compare the regression with the clinical observation.

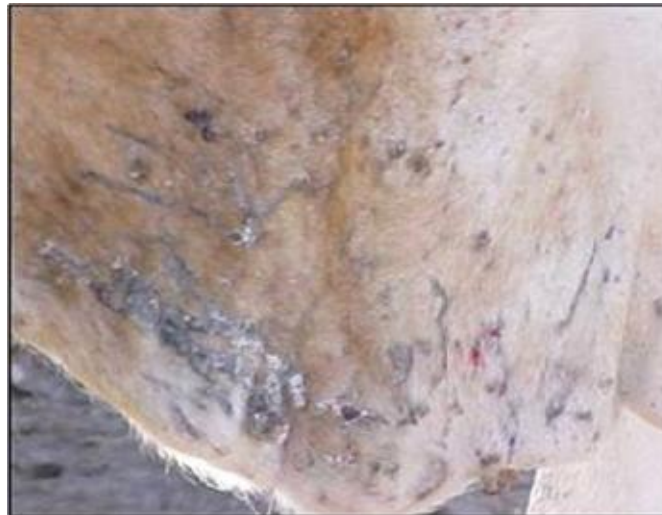

Figure 4. Clinical evaluation of the same female bovine after have being submitted to two doses of vaccine with fall and regression of the warts lesions and formation of scars in the epithelium scaly.

size from 5 to 10 mm at the largest axis were present. The animals submitted to the vaccination treatment were clinically accompanied for observation of lesion regression at a histological level (figure 3). Histologically, the tumors were characterized by fibroblastic proliferation with overlying acanthosis, orthokeratotic hyperkeratosis and parakeratosis cells. The tumor cells exhibited an infiltrative growth at the interface with normal tissue, expanding the dermis and surrounding moderate epithelial hyperplasia, as well as vacuous cytoplasm in the granular stratum, with presence of large and irregular

keratohyalin-like granules. Most cutaneous lesions were relatively characterized by productively infected keratinocytes degenerating into koilocytes, represented by clear cytoplasm around nucleic.

These features are characteristic of the cytopathic effect of PV infections. Follicular polyps were observed in hyperplastic derms characterizing the plane form of the papilloma. Clinically, the first signals of wart regression were observed after the second application of the inactivated autogenous vaccine (figure 4). Fifteen days after the last application of the vaccine, an intense

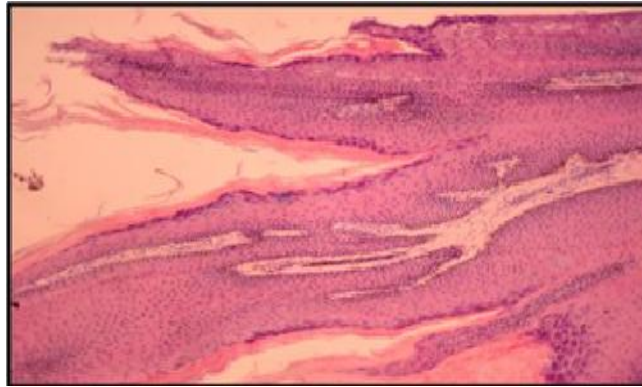


Figure 5. Fifteen days after the last vaccine application the microscopic exam revealed orthokeratotic hyperkeratosis without growth of the horny stratum due to a regression of the lesions and presence of discrete keratolysis and papillae with tracks of the epithelial layer. Obj.10x. H&E.

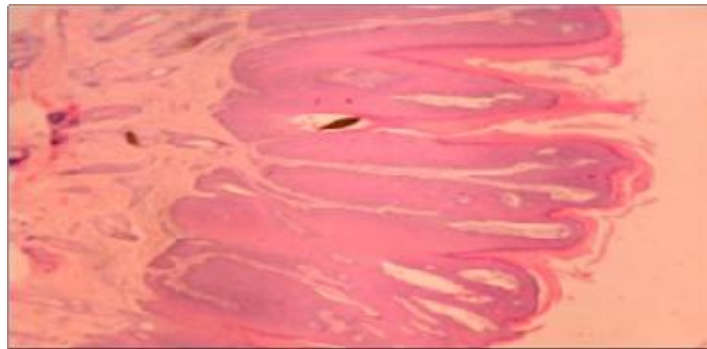


Figure 6. After 30 days vaccine treatment, the regularity of the disposition of the dermic papillae were observed as well as their height and thickness evidencing a situation close to normality. Obj.40x. H&E.

process of lesion regression began, developing into the detachment of the papillomas, confirmed histologically by moderate keratolysis, progressive degeneration of the verrucous tissue and formation of the epithelial tissue close to normality (figure 5 and 6). Among the 16 animals which were not vaccinated, regression and/or alterations of the cytomorphologic characteristics of the papillomas were not observed in the experiment.

DISCUSSION

The macroscopic aspects of the pedunculated and plane papillomas were similar to the description of Gerdes and Van der Lugt, (1991) and Santin and Brito, (2003). Microscopically, occasional areas of parakeratosis were also observed by Hayward et al.,

(1993), as well as the density of the stratified scaly epithelium (hyperkeratosis) and the proliferation of the thorny stratum (acanthosis) that were registered by Eisa et al., (2000). The koilocytosis was described initially as cells with nuclei picnotics, moderately irregular, outlined by extensive clear halos with superior volume than the cytoplasm (Silveira et al., 2005). The dyskeratosis occurs together with the koilocytosis and it consists densely of the premature keratinization in cytoplasm form densely eosinophilic, with opaque nucleus, hyperchromatic and irregular (Silveira et al., 2005). Other authors affirm that the koilocytosis constitutes a sign of pathognomonic infection by *papillomavirus* (Xavier et al., 2005). The histopathologic study is considered as method of screening lesions associated to the study of PV (Xavier et al., 2005). Oliveira et al., (2005) and Sundberg et al., (2000), observed in the benign lesions the presence of

great clear cells, displasic, with vacuous nuclei and prominent cytoplasm with granules of keratohyalin a characteristic of the viral cytopathic effect. Exophytic papillomatous proliferations are the most common form of cutaneous infection by *papillomavirus* but endophytic papillomas are also observed (Le Net et al., 1997). This was a pioneering study conducted in the field by clinical and histological comparative analyzing of the cutaneous warts samples collected before each dose of vaccine administered in the control group and experimental group of cattle vaccinated. The regressions of lesions were observed clinically and histologically in the 16 animals in group 2.

CONCLUSION

The histopathologic exams confirmed the clinical patognomonic findings of the tumor papillomatosis. The viral cytopathic effect was demonstrated in papiliform lesions independent of this morphology and the involution of the tumors compared clinically and histologically, considering the histopathologic exam an important method of diagnosis of the *papillomavirus* infection. The emergence of new papillomatosis neoformations was not verified during the observation period and the regression of the warts cutaneous lesions occurred due the vaccine program adopted for the experimental group.

ACKNOWLEDGMENTS

The authors acknowledge the Laboratory of Morphology and Pathological Anatomy, Veterinary Hospital from UENF by the technical collaboration in this work. This

work was supported by Carlos Chagas Filho Foundation for Research Support of the Rio de Janeiro State..

REFERENCES

- Sundberg JP, Van Ranst M, Montali R, Homer BI, Miller WH, Rowland Ph, Scott DW, England JJ, Dunstan RW, Mikaelian I, Jenson AB (2000). Feline papillomas and papillomaviruses. *Veter. Pathol.* 37:1-10.
- Souto R, Falhari JPB, Cross AD(2005). The Human papillomavirus: the factor related with the formation of neoplasias. *Revista Brasileira de Cancerologia.* 51 (2):155-160.
- Le Net JI, Orth G, Sundberg JP, Cassonnet P, Poisson L, Masson Mt, George C, Longeart L (1997). Multiple pigmented cutaneous papules associated with a novel canine papillomavirus in a immunosuppressed dog. *Veter. Pathol.* 34:8-14.
- Campo MS (1997). Bovine papillomavirus and cancer . *The Veter. J.* 154:175-188.
- Xavier SD, Son IB, Lancellotti CLP (2005). Prevalence of histological findings of human papillomavirus (HPV) in oral and oropharyngeal squamous cell carcinoma biopsies: preliminary study. *Revista Brasileira de Otorrinolaringologia.* 71(4):510-514.
- Gerdes Gh, E Van Der Lugtz JJ (1991). Electron microscopic evidence of the papillomavirus and the parapoxvirus in the same lesion. *Veter. Record,* 128 (25):594-595.
- Santin API, E Brito LAB (2003). Caracterização anatomopatológica da papilomatose cutânea em bovinos leiteiros. In: XI Encontro Nacional De Patologia Veterinária, São Paulo, p.220.
- Hayward MLR, Baird PJ, Meischke HRC(1993) Filiform viral squamous papillomas on sheep. *Veter. Record,* 132 (4):86-88.
- Eisa MI, El-Sawalhy AA, Abou-Ei-Fetouh MS(2000) Studies on bovine papilloma virus infection in cattle with trials of its treatment. *Veter. Med. J.* 48 (1): 47-55.
- Silveira LMS, Silva HA, Pereira IP (2005). Cytomorphologic criteria for the diagnosis of HPV and its relation with the gravity of cervical intraepithelial neoplasia. *Revista Brasileira de Análises Clínicas.* 37 (2): 127-132.
- Oliveira WRP, Grandson CF, Tying SNK (2005) Clinical aspects of epidermdysplasia verruciformis. *Clinical Laboratory and Therapeutic Investigation - Anais Brasileiro de Dermatologia,* 77 (5): 545-556.